

## PRONE BREAST RADIOTHERAPY IN EARLY-STAGE BREAST CANCER: A PRELIMINARY ANALYSIS

ALISON GRANN, M.D.,\* BERYL MCCORMICK, M.D.,\* ELIZABETH S. CHABNER, M.D.,\*  
SMITHA V. GOLLAMUDI, M.D.,\* KAREN D. SCHUPAK, M.D.,\* BORYS R. MYCHALCZAK, M.D.,\*  
ALEXANDRA S. HEERDT, M.D.,† THOMAS E. MERCHANT, D.O., PH.D.,‡ AND MARGIE A. HUNT, M.S.\*

Departments of \*Radiation Oncology and †Surgery, Memorial Sloan-Kettering Cancer Center, New York, NY; and ‡St. Jude Children's Research Center, Department of Radiation Oncology, Memphis, TN

**Purpose:** Women with large breasts have marked dose inhomogeneity and often an inferior cosmetic outcome when treated with breast conservation compared to smaller-sized patients. We designed a prone breast board, which both minimizes breast separation and irradiated lung or heart volume. We report feasibility, cosmesis, and preliminary local control and survival for selected women with Stage 0–II breast cancer.

**Materials and Methods:** Fifty-six patients with clinical Stage 0–II breast cancer were treated with lumpectomy and breast irradiation utilizing a prototype prone breast board. A total of 59 breasts were treated. Indications for treatment in the prone position were large or pendulous breast size ( $n = 57$ ), or a history of cardiopulmonary disease ( $n = 2$ ). The median bra size was 41D (range, 34D–44EE). Cosmesis was evaluated on a 1–10 (worst-to-best) scale.

**Results:** Acute toxicity included skin erythema (80% of patients experienced Grade I or Grade II erythema), breast edema (72% of patients experienced mild edema), pruritus (20% of patients), and fatigue (20% of patients reported mild fatigue). One patient required a treatment break. The only late toxicity was related to long-term cosmesis. The mean overall cosmesis score for 53 patients was 9.37 (range, 8–10). Actuarial 3- and 5-year local control rates are 98%. Actuarial overall survival at 3 and 5 years are 98% and 94%.

**Conclusion:** Our data indicate that treating selected women with prone breast radiotherapy is feasible and tolerated. The approach results in excellent cosmesis, and short-term outcome is comparable to traditional treatment techniques. This technique offers an innovative alternative to women who might not otherwise be considered candidates for breast conservation. © 2000 Elsevier Science Inc.

Breast cancer, Prone radiotherapy, Large breast size.

### INTRODUCTION

Standard treatment approaches for women with early-stage breast cancer include either local excision followed by adjuvant radiation or mastectomy. Randomized trials have shown similar survival with either treatment approach (1–6). Radiation therapy plays a critical role in the prevention of local recurrence after breast conservation (2, 6). The relationship between local failure and subsequent distant failure remains controversial; however, a large study strongly supports this hypothesis (7). Optimal radiation techniques usually prescribe 45–50 Gy to the whole breast over a period of 5 weeks. This is frequently followed by a boost, of 10–15 Gy, to the excisional biopsy site. In North America, the supine position is used, exaggerating the medial–lateral breast dimensions.

Large, pendulous, breast size has been a relative contraindication for breast conservation. A number of studies have demonstrated both increased acute toxicity and inferior cos-

metic outcome for large-breasted patients (8–12). Prosnitz *et al.* (13, 14) have reported that women with large, pendulous breasts, have increased fibrosis, a poorer cosmetic outcome, and have cautioned against the use of breast radiotherapy in this group. This poor cosmesis has been attributed primarily to the marked dose inhomogeneity within the breast, which may exceed 10% in these patients. In women with large, pendulous breasts, the medial-to-lateral separation of the patient typically exceeds 23 cm. Furthermore, the breast can fall quite laterally or cephalad when women with large breasts are treated in the standard supine position, and this can lead to an unacceptable volume of heart or lung in the radiation-treatment field. In addition, when the breast falls cephalad, it may be difficult to avoid the ipsilateral arm in the tangential field.

A number of institutions have reported different techniques to try to improve the treatment outcome of women with large breasts (15–19). These techniques aim to improve

Reprint requests to: Dr. Beryl McCormick, Department of Radiation Oncology, Memorial Sloan-Kettering Cancer Center, 1275 York Avenue, New York, NY 10021. E-mail: mccormib@mskcc.org

The authors do not have any financial interest in any company or product cited in this report.

Accepted for publication 6 January 2000.

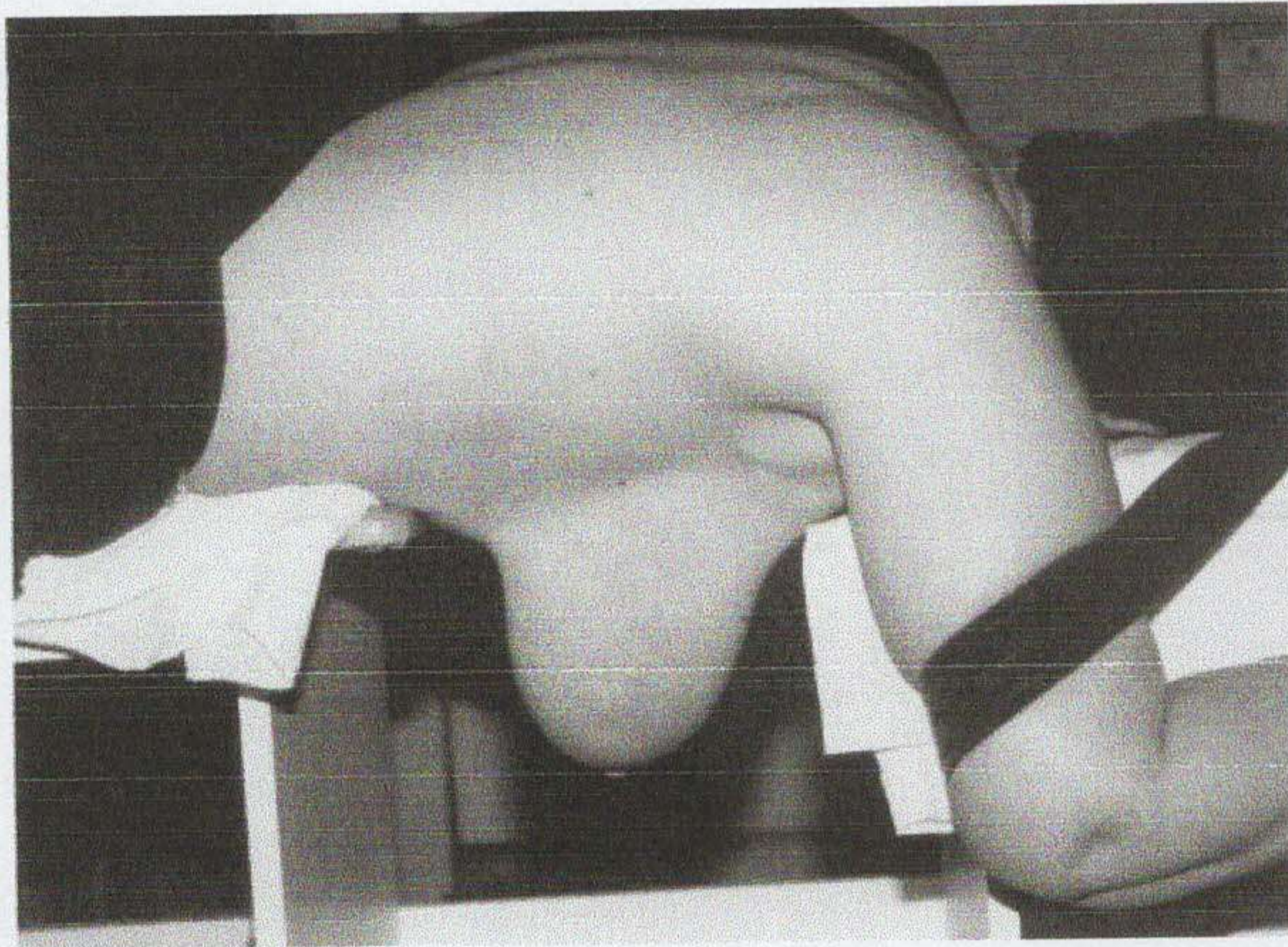


Fig. 1. Patient positioned for breast irradiation in the prone position. The breast hangs dependently through an opening in the treatment table.

the dose distribution within the breast, decrease acute toxicities, decrease the dose to normal tissue structures, and maximize daily reproducibility. We have designed a prone breast board to minimize breast separation and dose inhomogeneity within the treatment field. In addition, this technique decreases the irradiated lung and heart volume, and decreases the dose to the contralateral breast. The purpose of this study is to report feasibility and cosmetic outcome in women treated with our prone technique. We also report the preliminary local control and survival for selected women with early-stage breast cancer treated with this novel approach.

#### MATERIALS AND METHODS

Between 1992 and 1997, 56 patients with early-stage breast cancer were treated at Memorial Sloan-Kettering Cancer Center with conservative surgery and breast irradiation utilizing a prototype prone breast board (15). The median age was 63 years (range, 42–82 years). The objectives of the prone technique have been described previously (15). The patient at the time of simulation lies prone on a platform board (Fig. 1). An aperture in the board allows the breast to fall away from the chest wall, in a dependent fashion. In this position, excess tissue folds are minimized. The contralateral breast is placed on a custom support wedge (Fig. 2), and the patient is rotated slightly to allow the ipsilateral chest wall to extend into the board aperture. The medial, lateral, superior, and inferior borders of the target volume are determined clinically. The majority of our patients have had clips placed in the lumpectomy cavity at the time of surgery and we use these clips to define the primary tumor bed. If a patient has not had clips placed at the time of surgery, we review the preoperative mammogram and ultrasound to define the tumor bed. Patients are ineligible for the prone technique if the primary tumor is located within 1.5 cm of the chest wall. The patient is immobilized, and simulation is performed with a fixed SSD

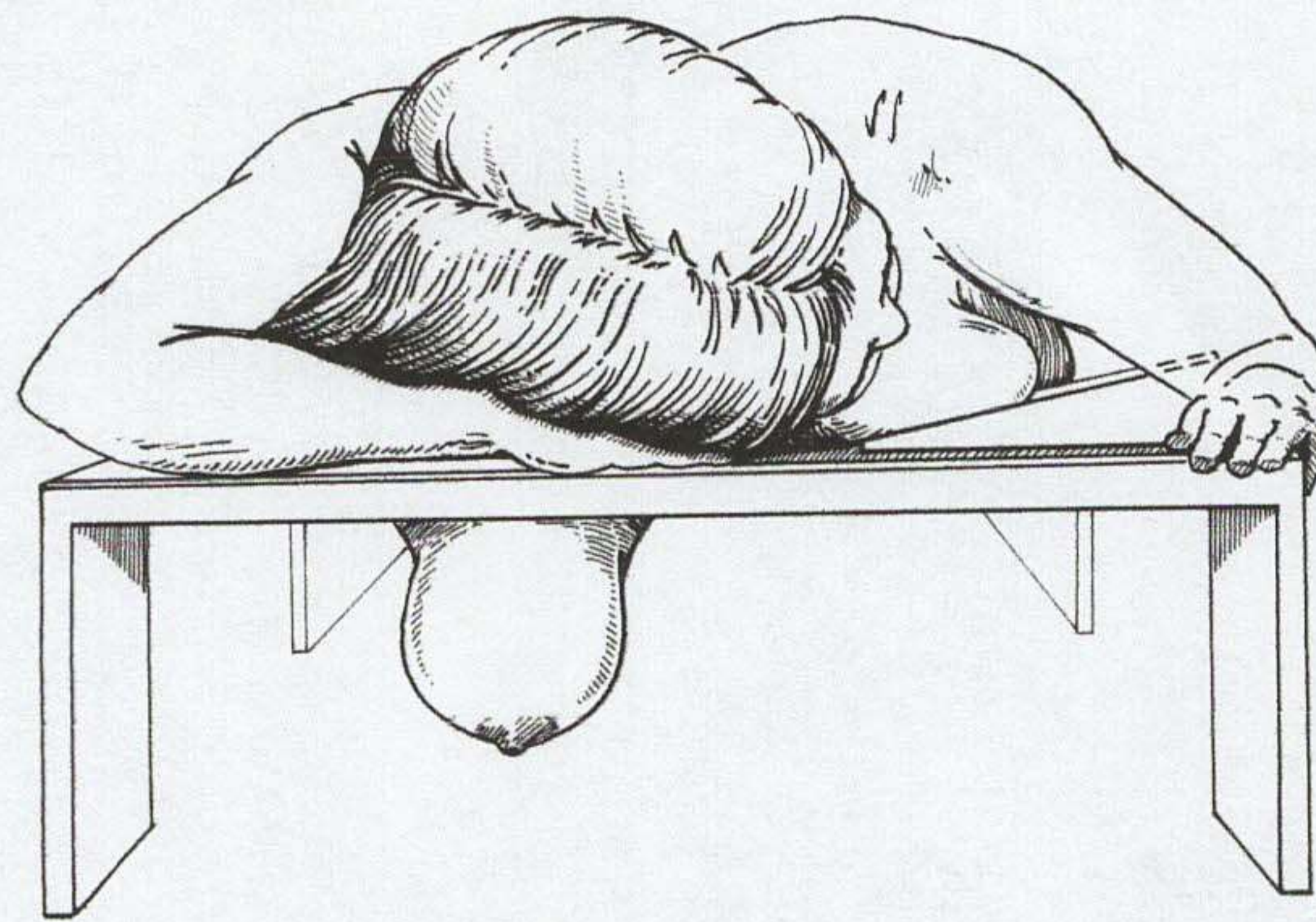


Fig. 2. Depiction of treated breast position with untreated breast on a custom wedge.

technique. Tattoos are placed at the field edges of the chest wall both laterally and medially. A transverse contour is taken at the level of the isocenter with the patient in the treatment position. The ribs are used as the most reliable radiographic landmark to provide the radiation oncologist with knowledge of the amount of chest wall, lung, and heart within the treatment portals.

All of the patients underwent either an excisional biopsy alone ( $n = 4$ ), or an excisional biopsy and axillary lymph node dissection ( $n = 55$ ). Axillary dissection consisted of removal of Level 1 and Level 2 lymph nodes. Nine of the 55 patients who underwent axillary lymph node dissection had positive lymph nodes (median, 3; range, 1–19). The primary pathologic diagnoses were ductal carcinoma *in situ* ( $n = 6$ ), invasive ductal or lobular carcinoma ( $n = 51$ ), and other invasive histologies ( $n = 2$ ). The final pathologic margin of resection was negative ( $> 2$  mm) in 52 patients (88%), close ( $< 2$  mm) in 6 patients (10%), and positive in 1 patient. The median tumor size was 1.2 cm (range, 0.3–4.0 cm).

Forty-two patients, (75%) received adjuvant systemic therapy. This included cyclophosphamide, methotrexate, and 5-fluorouracil (CMF) with or without doxorubicin (Adriamycin) (39%), or tamoxifen alone (36%). Six patients also received tamoxifen after they completed their systemic therapy. All patients completed their designed adjuvant treatment, except 1 patient treated for synchronous early-stage breast cancers who discontinued tamoxifen after 3 months.

A total of 59 breasts were treated, (2 women with synchronous and 1 woman with metachronous bilateral breast cancer). In the majority of cases ( $n = 57$ ), the indication for treatment in the prone position was a large or pendulous breast size. This was defined as a bra size of 40 inches, or a cup size of D or greater. The median bra size was 41D (range, 34D–44EE). The median patient separation in the prone position was 17 cm (range, 10–21 cm). Two of the patients included in our study were treated in the prone position because of a strong history of underlying cardiopulmonary disease, and the desire to minimize the heart and lung volume in the treatment field.

Radiotherapy consisted of treatment delivered with tangential fields to the entire breast. The typical beam angles used to deliver the radiation were 275° and 75° for the medial or lateral beam, depending on which breast was being treated. Depending on the shape of the breast, most but not all patients required compensating half-field wedges or full wedges to achieve optimal homogeneity. The regional lymphatics were not treated. The median dose was 46.8 Gy (range, 45–50.4 Gy) in 1.8- to 2-Gy fractions, 5 days a week. The isodose distributions were calculated for a transverse contour at the level of the field central axes and were normalized to a midplane point 1-cm anterior to the posterior field edge. The dose was prescribed to the 100% isodose line, which passed through the normalization point. Treatment was delivered using 6 MV photons. A boost to the tumor bed was delivered in 58 breasts treated. The breast boost was delivered either through an enface electron field ( $n = 27$ ), or with a medial, or lateral photon field ( $n = 31$ ). The median boost dose was 14 Gy (range, 6–14 Gy).

Cosmesis was evaluated on a 1–10 scale by an attending radiation oncologist or surgeon ( $n = 42$ ), or by a patient telephone interview ( $n = 11$ ). The cosmesis score has been outlined previously (11). In summary, the subjective analysis of cosmetic outcome was graded as follows: excellent = 9–10; good = 7–8; fair = 5–6; and poor = 4 and below. The cosmetic indices evaluated were symmetry, breast edema, skin thickening, breast tissue fibrosis, retraction, telangiectasia, and dimpling. An overall score served as a collective assessment of patients' cosmetic outcome. Toxicity was evaluated at each visit both during and after the completion of radiotherapy using the RTOG scale. The sites of failure were recorded for each patient. The sites of failure were characterized as either local (i.e., ipsilateral breast with or without other simultaneous sites of failure), isolated nodal, or distant. The median follow-up was 38 months (range, 16–81 months).

## RESULTS

Isodose distributions of a typical large-breasted patient simulated in both the supine and prone positions are shown in Fig. 3. This demonstrates the improvement in homogeneity in a breast plan when the patient is simulated in the prone vs. the supine treatment position. The traditional supine isodose distribution, which is normalized to a point at the lung–chest wall interface, is characterized by a hot spot at the apex of the breast, and at the periphery of the breast. This may be as much as 20% for very large patients. If lung inhomogeneity-correction factors are taken into account in the calculations, the peripheral hot spots may increase by approximately 5% in the classic supine position (9). Treatment in the prone position results in markedly improved homogeneity. This is primarily due to the decrease in the patient's separation. Figure 4 shows a typical simulation film of a patient in the prone position. Clips have been placed by the surgeon at the time of lumpectomy to define adequately the primary tumor bed. One can see that

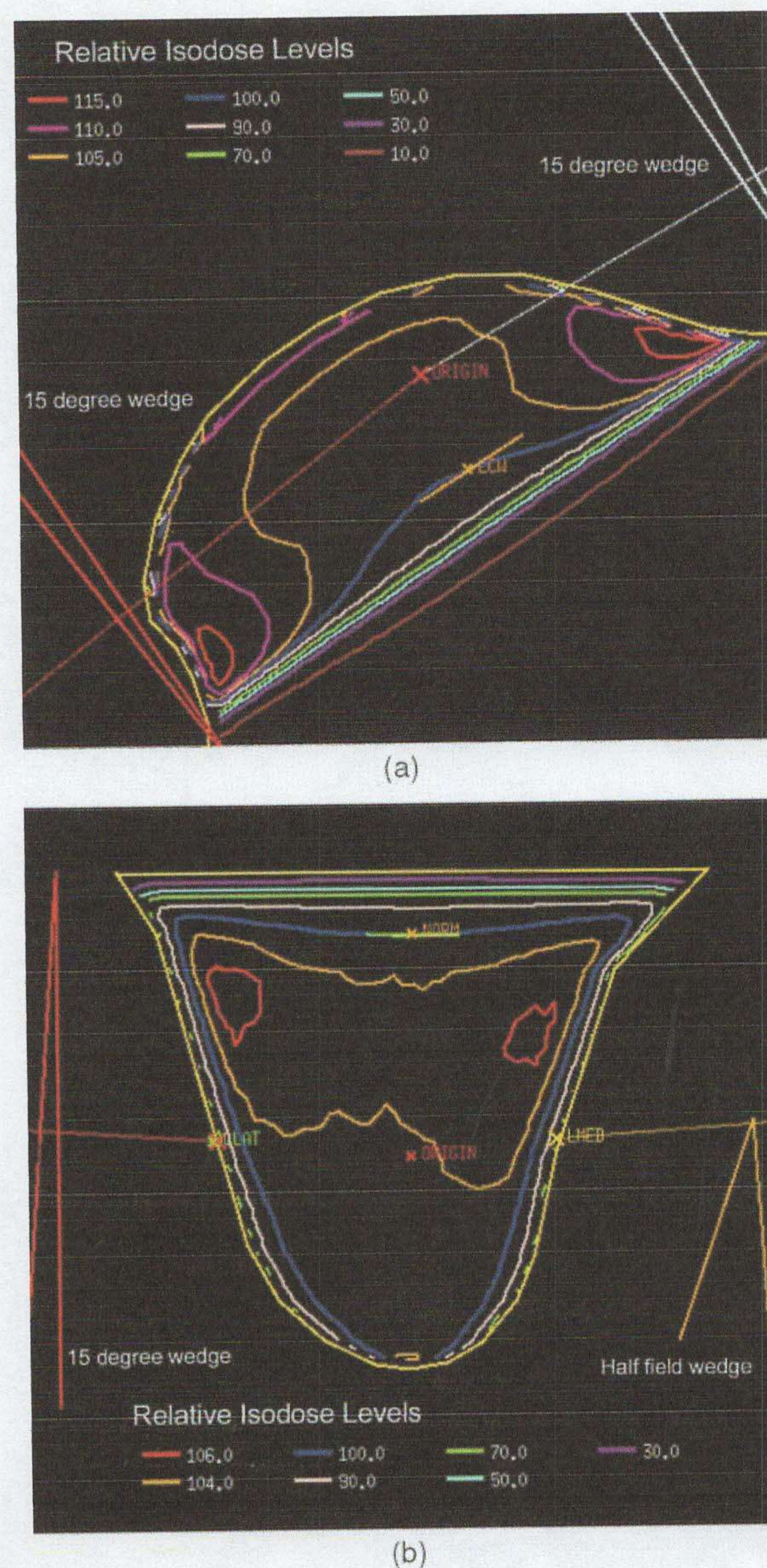


Fig. 3. Isodose distribution of a large-breasted patient in both the (a) supine and (b) prone positions with transverse contours taken at the center of the treatment field.

there is an adequate margin on the clips at the end of the simulation. Furthermore, the heart and lung can largely be avoided when patients are treated in this prone position. Respirations do not affect the breast position, as the breast is falling below the chest wall and the patient's chest is flat against the treatment table.

All patients were able to complete the prescribed course of external beam radiation therapy. Only 1 patient required a treatment break for Grade III moist desquamation. Eighty percent of patients experienced Grade-I or Grade-II skin erythema. Seventy-two percent of patients experienced mild breast edema, and no patients had pitting edema. Only 20% of patients developed pruritus, most commonly in areas of

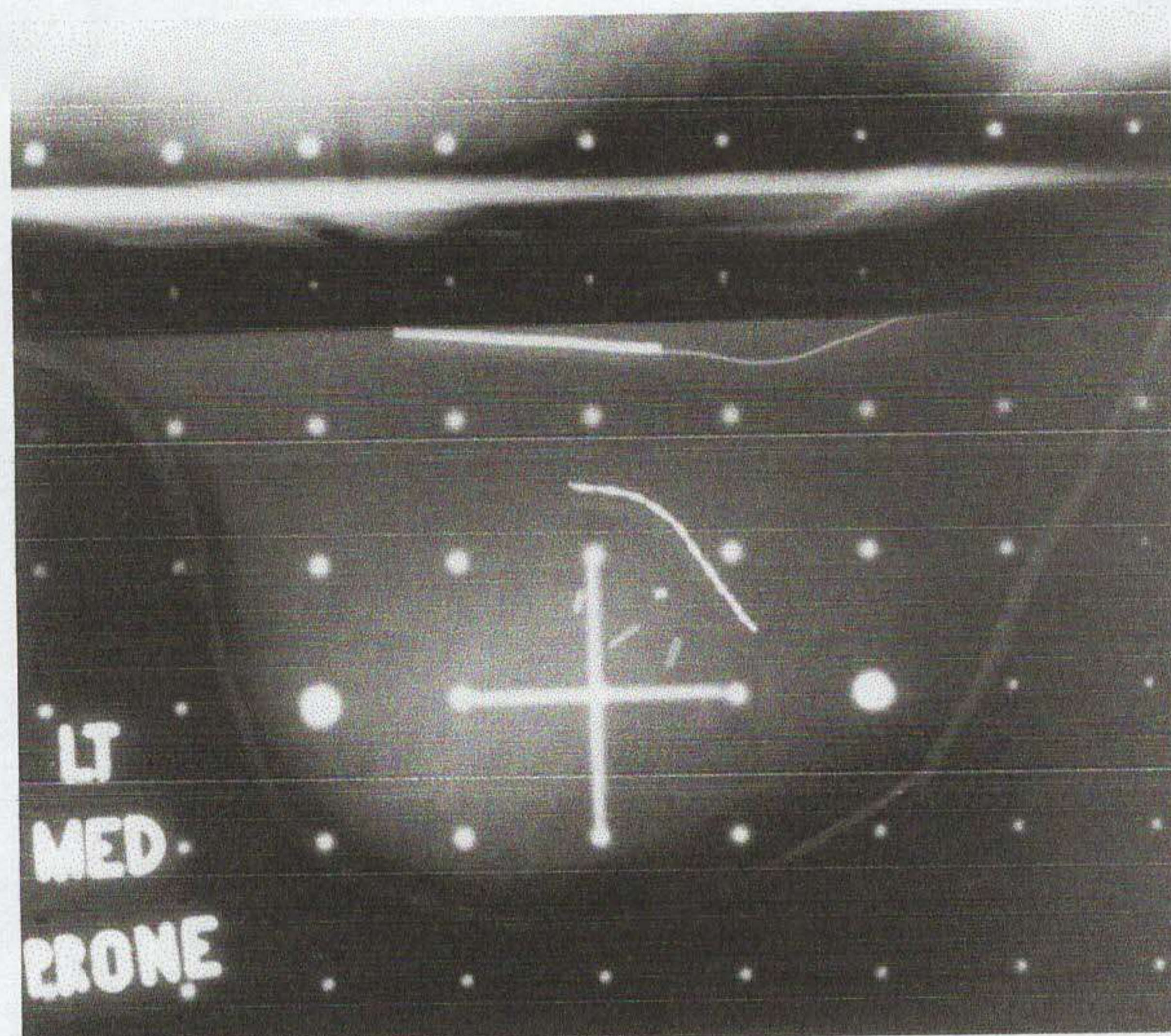


Fig. 4. Lateral simulation radiograph of a patient in the prone position. Clips outline the tumor bed. The posterior field edge includes the chest wall, and the remainder of the breast falls dependently through an aperture in the treatment table.

previous sun exposure. This resolved with the use of a mild steroid cream. Twenty percent of patients reported mild fatigue.

The only late toxicity in these 59 cases was related to long-term cosmesis. The mean overall cosmesis score for the 53 patients with data available was 9.37 (range, 8–10). Table 1 summarizes these results. An attending surgeon or radiation oncologist evaluated cosmesis in 42 patients. The mean cosmesis score for these 42 women was 9.5 (range, 8–10). Eleven patients responded to a questionnaire regarding cosmesis over the telephone. The mean cosmesis score for these 11 patients was 9.1 (range, 8–10). For the 42 patients whose cosmesis data was determined by their breast surgeon or radiation oncologist, 86% had an overall score of excellent. The most common parameter to decrease a patient's score from excellent to good was lack of breast symmetry. Twenty-two percent of patients scored 6–8 in this category. It was difficult to determine how much of the asymmetry was secondary to the surgery. Only 21% of patients had evidence of fibrosis, edema, or breast retraction. Fourteen percent had mild telangiectasia, or skin thickening. Dimpling was evident in 4% of the breasts over the prior biopsy site. All of the patients had an overall score of

Table 1. Cosmetic index scores (%)

	0-4	5	6	7	8	9	10
Symmetry	0	0	4	4	14	29	49
Edema	0	0	0	4	17	22	57
Skin thickening	0	0	0	0	14	31	55
Fibrosis	0	0	0	2	19	34	45
Retraction	0	2	0	5	14	22	57
Telangiectasia	0	0	0	7	7	7	79
Dimpling	0	0	0	0	4	8	88
Overall score	0	0	0	0	14	26	60

good or excellent, and to date there has been no significant difference in cosmesis for patients followed for less than vs. greater than 24 months. The median cosmesis scores were 9.5 and 9.8, respectively. The type of adjuvant therapy did not appear to impact on overall cosmesis. However, 75% of all of the patients included in our study did receive some form of adjuvant systemic therapy making it impossible to define the precise impact on cosmesis of systemic vs. no systemic therapy.

One patient experienced a local recurrence at 12 months and was salvaged with a modified radical mastectomy. Two patients have developed distant metastases at 46 and 52 months. Two patients died of other causes. The actuarial 3- and 5-year local control rates are 98%, which compares favorably with patients treated at our institution in the traditional supine position. The 3- and 5-year actuarial disease free survival rates are 100% and 88%, respectively. The actuarial overall survival rates at 3 and 5 years are 98% and 94%.

## DISCUSSION

Many women choose breast conservation as opposed to mastectomy. In terms of overall survival, breast conservation is considered an equivalent treatment to mastectomy for women with Stage I and II breast cancer (1–6). It is technically feasible to perform breast conservation in the majority of women with early-stage breast cancer. The main goals of lumpectomy and adjuvant radiation are to provide not only equivalent local control and survival as mastectomy, but to leave the patient with an excellent cosmetic outcome. The treatment of women with large, pendulous breasts is technically challenging to the radiation oncologist. Women with large breasts have increased acute and late toxicity when treated with radiation. There are two recognized reasons for the increased toxicity in this group. First, there is increased inhomogeneity due to the large separation between the two tangent fields. Second, excess skin folds have a bolus effect particularly in the inframammary and axillary regions.

Several investigators have previously reported poorer outcome among women with large breast size. Harris *et al.* (8) reported that large-breasted women suffered from increased breast fibrosis and retraction when treated with radiation. In his study, 31 patients were treated in the supine position with 4 MV photons. To determine the effect of breast size, patients were classified as having small, medium, or large breasts. They used a scoring system of 0–3 (0 = no change; 3 = severe changes). The average retraction and fibrosis scores for patients with small, medium, and large breasts were 0.75, 0.86, and 1.30 respectively. No statistical significance was found due to the small patient numbers. The authors suggested that the greater dose inhomogeneity in large-breasted patients might explain the difference.

Clarke *et al.* (18) observed poor cosmesis in women with larger breast size. He reviewed the records of 78 patients with Stage I and II breast cancer treated with lumpectomy

and radiotherapy with curative intent, and categorized breast size by bra cup size (A, B, C, D, or greater). Breast fibrosis was evident in 20% of patients with cup C or smaller breasts vs. 33% with a D size cup or greater. Analysis of the overall cosmetic result revealed a progressive decrease in overall cosmesis in patients with larger breasts. (A = 100%; B = 84%; C = 78%; D = 50%;  $p = 0.02$ ).

Gray *et al.* (11) also found increased asymmetry and retraction in women with large breasts treated in the supine position. The authors reviewed the cosmetic outcome of 257 patients treated with breast local excision and radiation therapy at MSKCC. They compared patients with average- vs. large-sized breasts. The large group was defined as weight of 80 kg or more, bra size of 40 inches or larger, cup size C or greater, or tangential separation of 23 cm or more. All patients were given a cosmetic score of 1–10 based on the same indices included in our current report. The average group scored higher on overall cosmesis 8.01 vs. 7.34 ( $p = 0.0004$ ). At 3- and 5-year follow-up, symmetry and retraction remained significantly different favoring the average group.

Ray *et al.* (12) also reported a negative correlation between breast size and cosmetic outcome. They reviewed 130 women with Stage I and II breast cancer treated with breast conservation. All patients were treated supine with 6 MV photons. They examined objective cosmesis as judged by the surgeon, and rated it on a four-tier scale from excellent to unsatisfactory, and they looked at functional cosmesis judged by the patients. The most common long-term toxicities were breast fibrosis and retraction. Of the 85 patients with small breasts (cup A or B), 92% had an excellent outcome compared to only 64% of the patients with larger breasts.

Recognizing the poorer cosmetic outcome in large-breasted women a number of institutions have reported on alternative radiation techniques to treat these women. Bentel *et al.* (16) at Duke University developed a simple immobilization ring, to position large, flaccid breasts in the supine position. They describe placing a reinforced polyvinylchloride tube formed ring around the breast. The breast tissue is manually moved to the desired position on the chest wall, and a strap is tightened around the patient to keep the breast and ring in position. They reviewed the results of 12 patients treated with this technique and found it to be both technically feasible and reproducible.

Algan *et al.* (20) reported a mock simulation of 11 patients; however, none of the patients were treated (21). An analysis of the examples given in that paper demonstrates a different setup than what we have described. Our prone breast board has an adjustable aperture, and we use a customized wedge to rotate the patient. The goals are that the posterior border is at the rib cage or deeper. The contralateral breast is pulled away with the required patient rotation to maximize the entire breast in the treatment field. In contrast, reviewing the examples given by Algan *et al.* (20), patient position was not optimized in this way. The lung chest-wall interface is as much as 6 cm above the

supporting table, with no effort to rotate the patients in two of the three examples given. In addition, the design of the Fox Chase board appears to compress the treated breast up toward the patient, rather than allowing it to hang freely, away from the patient.

Zierhut *et al.* (19) describe the use of a thermoplastic body mask to modify the position of the breast in 7 women with large breasts. In this series, patients were custom fit for the body mask in the supine position. Three-dimensional treatment plans and dose-volume histograms were generated and compared for each patient with and without the mask. The inhomogeneity ranged from  $-11\%$  to  $+20\%$  of the reference dose with a mean dose gradient of  $20.57\% \pm 3.46\%$ . The maximum follow-up was 1.5 years, and, at that time, the group described the overall cosmetic outcome as good.

Other authors have investigated alternative treatment positions. Baclesse initially described treatment in the lateral decubitus position in the 1950s (22). Fourquet *et al.* (23) published a report on the details of this technique. Of 783 patients treated at the Institute Curie, 644 (82%) were treated in the lateral decubitus position. The breast is treated with opposed photon beams tangent to the costal wall. Each beam is vertical, and the patient is rotated from side to side. Recognized drawbacks of this position include difficulty in reproducing the daily setup, and in estimating the dose distribution. However, investigators at the Institute Curie have considerable experience with this technique, and they report similar results in local control and survival when this group of patients is compared with those treated in the conventional supine position.

Cross *et al.* (24) have described 4 women with cup size EE breasts treated with a modified lateral decubitus technique. A styrofoam mold was made to maintain the breast in the proper position during treatment and assure daily reproducibility. This position decreased the patient separation in 3 of the 4 patients and allowed an improvement in the dose homogeneity. All 4 women experienced moist desquamation in the intramammary fold by the end of treatment. The skin toxicity was attributed to the bolus effect styrofoam mold. A parallel plate chamber showed that the surface dose increased from 40% to 80% with and without the mold in place. Using the cosmetic scoring system devised and reported by Harris *et al.* (8), they found cosmesis to be excellent in 3 patients and good in the 4th.

Another technique that has been used to treat women with a large separation is a higher energy beam ( $\geq 10$  MV) and a beam spoiler. Although this technique may improve dose homogeneity in this group of patients, the presence of the beam spoiler may significantly increase the dose to the opposite breast (25). In addition, in large-breasted patients, the supine technique with high-energy photons and a beam spoiler does not help to decrease a patient's multiple skin folds or to minimize the amount of heart and lung in the treatment field.

A prone breast board was designed at Memorial Sloan-Kettering Cancer Center both to improve dose distribution and to decrease the volume of normal tissues irradiated

during whole breast treatment. Merchant *et al.* (15) found that the high-dose region at the base of the breast could be reduced from 116% to 118%, for large-breasted women treated in the supine position, to 102–103% for the same woman treated in the prone position. The authors also showed a decrease in the amount of normal lung and heart included in the treatment fields, and a decreased dose to the contralateral breast. Our paper reports on 56 patients with 59 breast cancers treated in the prone position. Overall cosmesis was excellent in 86% of the patients. These results appear to be similar to the results of small-breasted patients treated in the supine position (18, 26).

The original cosmesis scale reported by Harris *et al.* (8) placed patients into four categories. An excellent score was given to women when the treated breast appeared nearly identical to the untreated breast, a good result if the treated breast was slightly different, fair when the treated breast was clearly different, and poor when the treated breast was seriously distorted. Several authors have questioned the usefulness of subjective evaluations of cosmesis (19, 27). Instead of requiring patients to be placed into four discrete cosmesis categories, our approach allows an observer to evaluate all patients on a graduated scale of 1–10, with separate analysis of several criteria (11). This graduated scale of values minimizes the necessity to group patients less precisely into a broad category. It also allows a separate analysis of which particular cosmetic indices are most affected by lumpectomy and radiation therapy in large-breasted women. Although patients were not enrolled prospectively and were not followed by one physician over time, we feel that our results overall demonstrate better long-term cosmesis than has been recognized when treating these patients with the classic supine technique.

Another important component of this treatment technique is that it minimizes the amount of normal organs in the treatment field. Bieri *et al.* (28) studied dose distributions in a Rando–Alderson phantom, modified with a simulated left breast tissue-equivalent material. They evaluated treatment in both the supine and prone position. The authors concluded that tangential radiotherapy delivered in the prone position significantly reduced secondary doses to peripheral tissues, compared with tangential radiotherapy in the supine position. Prone breast tangents resulted in ipsilateral integral lung doses, which were three- to four-times lower than those seen with supine treatment did. Furthermore integral

bone marrow doses were reduced by 40–75%. Direct cardiac irradiation was completely avoided in the prone position. One of the technical challenges in breast irradiation is to minimize treatment to the underlying lung and heart. Two of the patients in our study were treated in the prone position for underlying cardiopulmonary disease, and to date have not suffered increased short, or long-term toxicity with radiation. Data is needed on a larger subset of patients to draw definitive conclusions about prone treatment in this subset of patients.

Although these data is relatively immature for breast cancer, reports in the literature have stated that fibrosis and retraction remain stable 30–36 months following treatment (26). The median follow-up in this study is 3 years. Observer-based cosmesis has been criticized (27). Beadle *et al.* (29) found that patients were more likely than physicians to judge their cosmetic outcome as excellent. The results of the 11 patients who answered the telephone survey on cosmesis are similar to the physician's scores and add credibility to our results.

There are a number of similarities between our technique and that used at the Institute Curie (22, 30). The lateral decubitus technique, like our prone technique, aims to minimize the patient's separation, and cardiopulmonary irradiation is reduced. In both techniques, meticulous patient setup is required daily. A limitation of both techniques is that they can not adequately cover the regional lymphatics. Although our follow-up is short, local control and survival appear to be equivalent to similar-staged patients treated in the supine position (1–6).

In conclusion, we report the results of 59 breasts treated in the prone position. Overall cosmesis appears to be excellent, and preliminary data on local control and survival to date appear comparable to patients treated in the supine position. Additional treatment of patients with underlying heart and lung disease is necessary to draw definitive conclusions on the use of the prone treatment in this subset of patients. In addition, longer follow-up is necessary to define whether or not this technique will result in a decrease in the long-term toxicity to the heart, lung, and a reduction in secondary malignancies. We currently treat the majority of patients with early-stage breast cancer, and large pendulous breasts, in the prone position. This technique offers an innovative alternative for women who might not otherwise be considered candidates for breast conservation.

## REFERENCES

1. Lichter AS, Lippman ME, Danforth DN. Mastectomy versus breast-conserving therapy in the treatment of stage I and II carcinoma of the breast: A randomized trial at the National Cancer Institute. *J Clin Oncol* 1992;10:976–983.
2. Blichert-Toft M, Roce C, Anderson JA, *et al.* Danish randomized trial comparing breast conservation therapy with mastectomy: Six years of life-table analysis. Danish Breast Cancer Cooperative Group. *J Natl Cancer Inst Monographs* 1992;11:19–25.
3. Veronisi U, Banfi A, Salvadori B, *et al.* Breast conservation is the treatment of choice in small breast cancer: Long-term results of a randomized trial. *Eur J Cancer* 1990;26:668–670.
4. van Dongen J, Bartelin H, Fentiman IS, *et al.* Randomized clinical trial to assess the value of breast-conserving therapy in stage I and II breast cancer, EORTC 10801 trial. *J Natl Cancer Inst Monographs* 1992;11:5–18.
5. Sarrazin D, Le MG, Arriagada R, *et al.* Ten-year results of a randomized trial comparing a conservative treatment to mastectomy in early stage breast cancer. *Radiother Oncol* 1989;14:177–184.

6. Fisher B, Anderson S, Redmond CK, *et al.* Reanalysis and results after 12 years of follow-up in a randomized clinical trial comparing total mastectomy with lumpectomy with or without irradiation in the treatment of breast cancer. *N Engl J Med* 1995;333:1456–1461.
7. Fortin A, Larochelle M, Laverdiere J, *et al.* Local failure is responsible for the decrease in survival for patients with breast cancer treated with conservative surgery and postoperative radiotherapy. *J Clin Oncol* 1999;17:101–109.
8. Harris JR, Levene MB, Svensson G, *et al.* Analysis of cosmetic results following primary radiation therapy for stages I and II carcinoma of the breast. *Int J Radiat Oncol Biol Phys* 1979;5:257–261.
9. Chin LM, Cheng CW, Siddon RL, *et al.* Three-dimensional photon dose distributions with and without lung corrections for tangential breast intact treatments. *Int J Radiat Oncol Biol Phys* 1989;17:1327–1335.
10. Buchholz TA, Gurgoze E, Bice WS, *et al.* Dosimetric analysis of intact breast irradiation in off-axis planes. *Int J Radiat Oncol Biol Phys* 1997;39:261–267.
11. Gray JR, McCormick B, Cox L, Yahalom J. Primary breast irradiation in large-breasted or heavy women: Analysis of cosmetic outcome. *Int J Radiat Oncol Biol Phys* 1991;21:347–354.
12. Ray GR, Fish VJ. Biopsy and definitive radiation therapy in stage I and II adenocarcinoma of the female breast: Analysis of cosmesis and the role of electron beam supplementation. *Int J Radiat Oncol Biol Phys* 1999;9:813–818.
13. Prosnitz LR, Goldenberg IS, Harris JR, *et al.* Radiotherapy for carcinoma of the breast instead of mastectomy. *Front Radiat Ther Oncol* 1983;17:69–75.
14. Prosnitz LR, Goldenberg IS, Packard RA, *et al.* Radiation therapy as initial treatment for early stage cancer of the breast without mastectomy. *Cancer* 1977;39:917–923.
15. Merchant TE, McCormick B. Prone position breast irradiation. *Int J Radiat Oncol Biol Phys* 1994;30:197–203.
16. Bentel GC, Marks LB. A simple device to position large/flaccid breasts during tangential breast irradiation. *Int J Radiat Oncol Biol Phys* 1999;29:879–882.
17. Monson JM, Chin L, Nixon A, *et al.* Is machine energy (4–8MV) associated with outcome for stage I–II breast cancer patients? *Int J Radiat Oncol Biol Phys* 1997;37:1095–1100.
18. Clarke D, Martinez A, Cox R. Analysis of cosmetic results and complications in patients with stage I and II breast cancer treated by biopsy and irradiation. *Int J Radiat Oncol Biol Phys* 1983;9:1807–1813.
19. Zierhut D, Flentje M, Frank C, *et al.* Conservative treatment of breast cancer: Modified irradiation technique for women with large breasts. *Radiother Oncol* 1994;31:256–261.
20. Algan O, Fowble B, McNeeley S, *et al.* Use of the prone position in radiation treatment for women with early stage breast cancer. *Int J Radiat Oncol Biol Phys* 1998;40:1137–1140.
21. Fowble B. Personal communication. 1999.
22. Baclesse F. Five-year results in 431 breast cancers, treated solely by roentgen rays. *Ann Surg* 1965;161:103–104.
23. Fourquet A, Campana F, Rosenwald JC, Vilcoq JR. Breast irradiation in the lateral decubitus position: Technique of the Institute Curie. *Radiother Oncol* 1991;22:261–265.
24. Cross MA, Elson HR, Aron BS. Breast conservation radiation therapy technique for women with large breasts. *Int J Radiat Oncol Biol Phys* 1989;17:199–203.
25. Michaletz-Lorenz M, Klein EE, Taylor ME. Use of a lucite beam spoiler for high energy breast irradiation (Abstr.). *Int J Radiat Oncol Biol Phys* 1994;30(Suppl. 1):327.
26. Olivotto IA, Rose MA, Osteen RT, *et al.* Late cosmetic outcome after conservative surgery and radiotherapy: Analysis of causes of cosmetic failure. *Int J Radiat Oncol Biol Phys* 1989;17:747–753.
27. Pezner RD, Lipsett JA, Vora NL, *et al.* Limited usefulness of observer-based cosmesis scales employed to evaluate patients treated conservatively for breast cancer. *Int J Radiat Oncol Biol Phys* 1999;11:1117–1119.
28. Bieri S, Russo M, Rouzard M, *et al.* Influence of modifications in breast irradiation technique on dose outside the treatment volume. *Int J Radiat Oncol Biol Phys* 1997;38:117–125.
29. Beadle GF, Silver B, Botnick L, *et al.* Cosmetic results following primary radiation therapy for early stage breast cancer. *Cancer* 1984;54:2911–2918.
30. Calle R, Pilleron JP, Schlienger P, *et al.* Conservative management of operable breast cancer; ten year experience at the Foundation Curie. *Cancer* 1978;42:2045–2053.